

## Morphological Anatomy of Splenic Artery and its Clinical Implications

Bhivate Varsha R.\*, Kharate Rahul P.\*\*, Ujjawal Narpatsingh\*\*\*, Gaikwad Jyoti R.\*\*\*\*

### Abstract

**Context:** To study morphological Anatomy of splenic artery and its clinical implications. **Aims:** The present study reports; origin, course, distance of division from the hilum of spleen and branching pattern of splenic artery. **Setting and design:** Department of Anatomy MGM medical college, navimumbai. **Material and method:** The measurements were taken on 50 donated embalmed cadavers. The findings were noted after meticulous dissection. **Results:** The origin of splenic artery is from splenic artery in all cases. In relation to pancreas the splenic artery had suprapancreatic course in 74% followed by anteropaneatic in 18%, intrapancreatic in 6% and retropancreatic in 2%. In two cadavers the stem of the artery divided into two or three branches which has either suprapancreatic or anteropaneatic course. The splenic trunk divided into two primary branches in 84% and three primary branches 16%. Superior polar artery was present in 28%, inferior polar artery was present in 42% and in 12% both superior and inferior polar arteries were seen. The mean distance of the point of division of splenic artery from the hilum was 4.308 cm and minimum was 3.1 cm. It is found that primary branches and polar branches of splenic artery divide the spleen into segments. In our study the segmental branches were 2 in 84% and 3 in 16%. **Conclusion:** Knowledge of splenic artery has the clinical significance in planning and conducting procedures such as partial or total splenectomy, splenic embolisation, splenography and surgical and radiological procedures of upper abdominal region to avoid any complications.

**Keywords:** Splenic artery; Branching pattern; Hilum; Course; Splenectomy.

### Introduction

Variations of origin and course of arteries of different organs are not only of anatomical and embryological interest but also of practical and clinical importance when these variations can be the agents of pathological conditions or in surgery when knowledge of them can result in more accurate treatment.[1]

Surgery of the organs of the supracolic part of the abdomen requires a thorough knowledge of the vascular anatomy of this region. The vascular anomalies are due to the aberration in the embryological development. Embryologically the splenic artery is one of the branches of the artery of foregut, i.e. celiac trunk. It passes horizontally to the left, behind the stomach, along the upper border of the pancreas. Near the tail of the pancreas it enters in the lienorenal ligament and then divides into five or more terminal branches that enter the hilum of the spleen and spleen is supplied exclusively by splenic artery.[2]

The present study reports origin, course, distance of division of splenic artery from the hilum of spleen and branching pattern of the splenic artery.

**Author's Affiliation:** \*MD Anatomy, Assistant Professor, Terna Medical College, Nerul, Navimumbai, \*\*MD Anatomy, Assistant Professor, \*\*\*MS Anatomy, Professor, MGM Medical College, Kamothe, Navimumbai, \*\*\*\*MS Anatomy, Associate Professor, Terna Medical College, Nerul, Navimumbai, Maharashtra, India.

**Reprint's Request:** Dr. Bhavate Varsha R., B-106, Shankar Tower, Plot 14, Sector 14, Sanpada, Navimumbai 400705, Maharashtra, India.

E-mail: varshabhivate@gmail.com

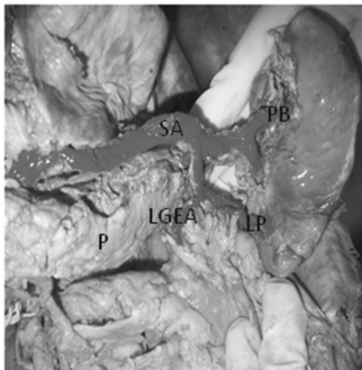
## Materials and Methods

The present study was conducted in Dept of Anatomy MGM Medical College, Kamothe, Navi Mumbai. The study was conducted on 50 embalmed donated cadavers. The study technique consisted of meticulous dissection, observations and measurement of various parameters.

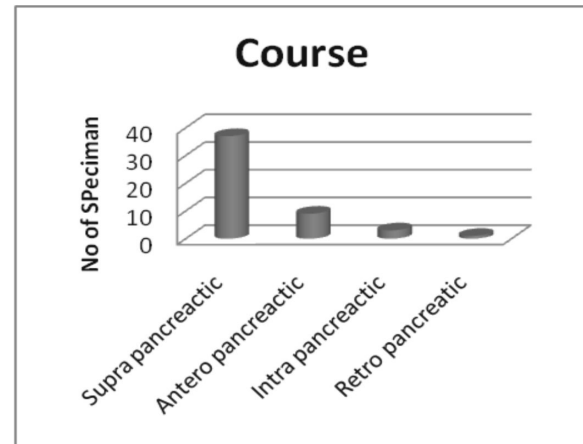
In each cadaver, an incision was made in the midline from xiphoid process till the umbilicus and extended it till pubic symphysis encircling the umbilicus. A curved incision was made from anterior superior iliac spine to public symphysis. Skinflaps and superficial fascia were reflected by blunt dissection according to Cunningham.[3] The external oblique, internal oblique and transverous abdominis muscles were reflected. The rectus sheath, fascia transversalis and peritoneum were divided. Celiac trunk exposed. The tail of pancreas and lineorenal ligament identified and terminal branches of the splenic artery dissected and counted.

The origin and course of splenic artery dissected along with pancreas. Distance between point of divisions of splenic artery and splenic hilum was measured by using measuring tape and thread. Its variations about origin, course, distance from division

**Figure 1: Suprapancreatic course of splenic artery and Inferior polar branch arising from left gastroepiploic artery. (SA-splenic artery, PB-primary branches, LP-lower polar branch, LGEA-left gastroepiploic artery)**



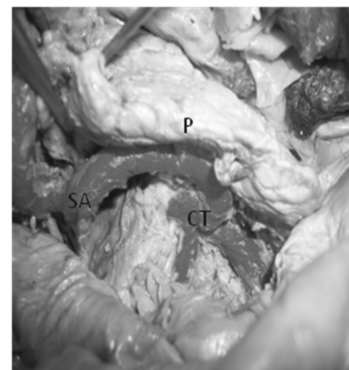
**Graph 1: Histogram showing distribution of splenic artery in relation to pancreas along with confidence interval**



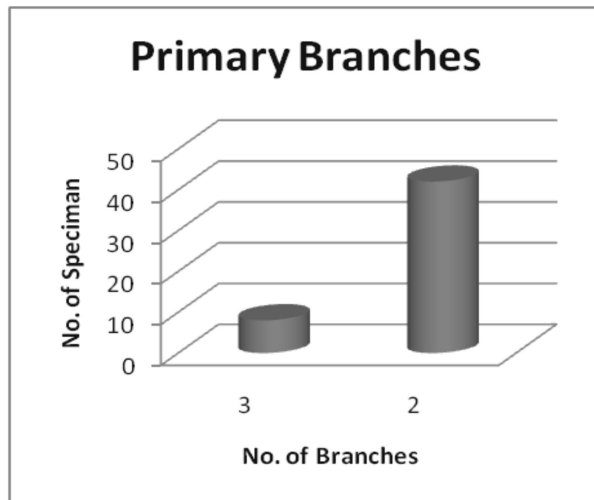
and branches were observed and noted down. Any of the variations in the term of numbers of segmental branches if present noted.

The present study deals with the variations of only branches of splenic artery that enter spleen. The pancreatic branches, short gastric branches of splenic artery were not taken into consideration. The photographs of the study and if any variation found, were taken. All these data were tabulated and subjected to appropriate statistical test.

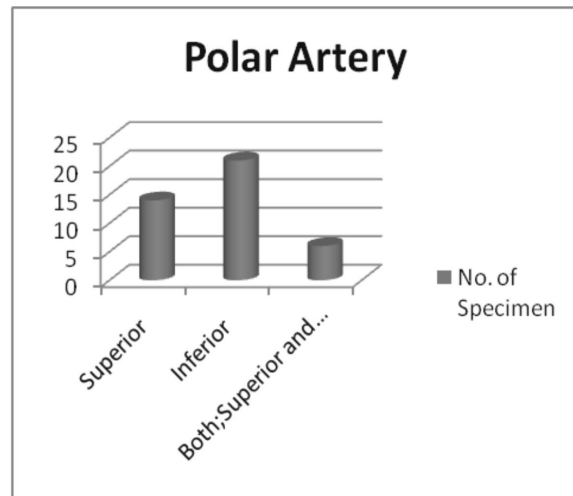
**Figure 2: Retropancreatic course of splenic artery and origin from celiac trunk. (P-pancreas, SA-splenic artery, CT-ceeliac trunk)**



**Graph 2: Histogram showing primary branches of splenic artery.**



**Graph 3: Histogram showing distribution of polar artery**

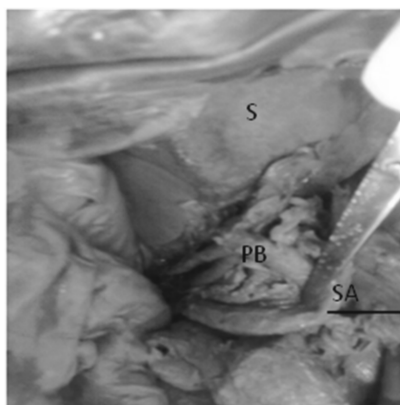


**Results**

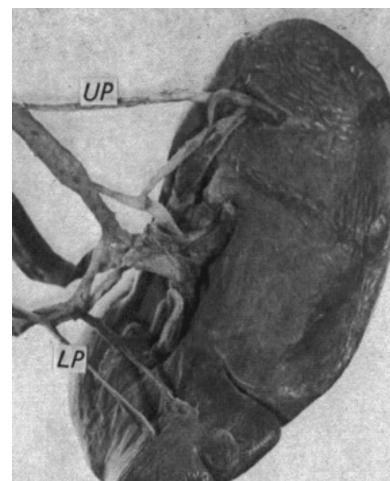
The origin, course, distance of division from hilum and branching pattern of splenic artery were studied in 50 human cadavers. Out of 50 cadavers, the splenic artery originated from celiac trunk in all 50 cadavers (figure 2). In relation to pancreas the splenic artery had suprapancreatic course in 37 cadavers (figure 1) followed by anteropaneatic in 9, intrapancreatic in 3 and retropancreatic (figure 2) in 1 cadaver (graph 1). In two cadavers the stem of the artery divided into two or three branches which has either

suprapancreatic or anteropaneatic course. Such an aberrant course makes the artery vulnerable to iatrogenic injury during intervention of pancreas. The splenic trunk divided into two primary branches in 42 cadavers and three primary branches (figure 3) in 8 cadavers (graph 2). In the present study, polar arteries were also found (figure 4). In 14 [28%] spleens, superior polar artery was present whereas in 21 [42%] spleens, inferior polar artery was present (figure 1) and in 6 [12%] both; superior and inferior polar

**Figure 3: Splenic artery and 3 primary branches. (S-spleen, PB-primary branches, SA-splenic artery)**



**Figure 4: Showing upper and lower polar branches. (UP-upper pole branch, LP-lower pole branch)**



#### Graph 4: Histogram showing distance of division from the hilum

arteries were seen (graph 3). The segmental branches divided in too many generations but did not show any anastomosis, so they were described as end arteries. The mean distance of the point of division of splenic artery from the hilum was 4.308 cm and minimum was 3.1 cm (table 1). It is found that primary branches and polar branches of splenic artery divide the spleen into segments. These segments are separated by avascular planes by segmental branches. In our study the segmental branches were 2 in 84% and 3 in 16%.

#### Discussion

In the current study, splenic artery was arising from celiac trunk in all cases (100%). This finding was comparable to the study of Vandamme JP and Bonte J who observed that celiac trunk composed of 3 main stems splenic, hepatic and left gastric. The variation of the origin of splenic artery was exceptional.<sup>[4]</sup> Also this finding was in agreement with other studies done by Jauregui E, Moore and Delly,

Y. Mikhal, R Kamel, N.N. Nawan and M.F.M Rafela who showed that the splenic artery originated from celiac trunk in all cases.<sup>[5,6]</sup> Also in 2011, Ambica Wadhawa and Sandeep Soni found that in 94% of cases they studied, celiac artery was a common trunk of origin for the 3 branches. In 6% cases left gastric origin was different.<sup>[1]</sup> This finding of the splenic artery was similar to our study.

Many earlier reports by Lipshutz in 1917, Hollinshed and Ross in 1985, Sponza *et al* in 1993, Vatnaki *et al* in 1995, Slaba *et al* in 1998 showed that if the splenic artery not arising from the celiac trunk, then it had an aberrant origin either from aorta, superior mesenteric or left gastric arteries.<sup>[2]</sup> But these findings were not observed in our study.

The course of splenic artery followed the superior border of pancreas according to William *et al* (1995). Study done by Redmond *et al* showed that the splenic artery follows the suprapancreatic course in majority of cases but in few cases it has either retro or intrapancreatic course.<sup>[7]</sup> In 2004, S. K. Pandey, V. K. Shukla showed that suprapancreatic course was commonly observed, followed by anteroppancreatic, intrapancreatic and retropancreatic course. These findings were similar to our study.<sup>[2]</sup>

In the present study it is found that the artery follows the superior border of the retropancreatic or intrapancreatic course. The variation in the course of the artery in relation to the pancreas might be due to the abnormal fusion of the ventral and dorsal bud as reported earlier (Ozan and Onderglu 1997).<sup>[2]</sup>

We further observed that in two cadavers the stem of the artery divided into two or three branches which had either suprapancreatic or anteroppancreatic course. Such an aberrant course makes the artery vulnerable to iatrogenic injury during intervention of

**Table 1: Showing distance of division from the hilum**

Distance of division	Minimum	Maximum	Mean	Standard Deviation	Variance
	3.1	5.9	4.368	1.03123	1.063

pancreas.

In Aug 2001, Muzaffer Sindel, Levent Sarikcioglu, Kagan Ceken, Satm Yilmaz had measured the distance between the origin of the last pancreatic branch and the splenic hilum in digital angiogram and cadaver specimen. In anatomical measurement it was 3.9+0.78 cm and angiographically it was 3.75 + 0.68 cm. Similarly in our study the distance between the point of division of splenic artery into primary branches and the hilum was 4.368 cm. In 50 specimens, maximum distance was 5.90 cm, minimum distance was 3.10cm, deviation was 1.0312 and variance was 1.063. Mean distance from the hilum was 4.3680 cm which was slightly greater than the above study.[8] The point of division of splenic artery was not constant, being quite close to the hilum or several centimeters from it, as previously reported by Piquand, Volkman and Gupta.[9] In 1999, Jauregui E, showed that the distance between the extremity of pancreas and the splenic hilum was 2.2 cm with final ranging from 0 to 4 cm.[5]

Y. Mikhial, R Kamel, N. N. Y. Nawar and M.M.M. Rafela found that 2/3<sup>rd</sup> of the cases splenic artery was divided into two terminal branches. Lipshutz also found that the splenic artery divided into two terminal branches in 72% and three terminal branches in 28%. These two studies were similar to our study in which we found that splenic artery was divided into three primary branches in 16% and two primary branches in 84%.[6]

In 1999, Jauregui E and in 1989 Redmond H P found that in 100% cases splenic artery divided into two primary branches which was similar to our study whereas S. K. Pande , S. Bhattacharya, R. N. Mishra, V. K. Shukla (2003) showed that two terminal braches were most common followed by 4, 6 and more than that. These finding were not similar to our study.[5,6]

C. D. Gupta, S. C. Gupta, A. K. Arora and P. Jeyasingh in their corrosion case study prevailed that the splenic segment formed by

2 primary branches in 84% and three in 60%. These segments were separated by avascular planes lying perpendicular to long axis of the spleen. Each primary branch was found to supply a definite segment of spleen with only slight overlapping and without an apparent anastomosis between the vessels of adjacent segments. These finding were similar to our study.[9]

According to Y. Mikhail, R, Kamel, N. N. Nawar and M. F. M. Rafela, avascular planes between the segments coinciding with the deep notches on the external faces of spleen separated by the territories were supplied by these splenic arteries. Such planes divided the spleen in two lobes. The splenic lobes could be 2-5 in number. The additional lobes were found when polar arteries were present. They showed that in 12% of spleens there were both upper polar and lower polar arteries, in another 12% only upper polar arteries were present and in 50% presented with lower polar arteries. In our study we found that in 28% upper polar, in 42% lower polar and in 12% cases both upper and lower polar was present. Knowledge of variations of splenic artery is of extreme clinical importance while performing Appleby procedure that is total pancreatectomy in case of carcinoma of pancreas body and tail. Surgeons must have a knowledge regarding branching pattern of splenic artery or else there is a possibility of dangerous bleeding if damaged. [10] With the development of techniques of arteriography, the knowledge of arteries and of their variations has acquired a special importance for correct interpretation of the different and sometimes very complicated pictures.[1]

## Conclusion

From the present study we conclude that,

- Splenic artery follows the suprapancreatic course in majority of cases (74%), but anteroppancreatic in

18%, intrapancreatic 46% and retropancreatic 2%. In two cadavers the stem of the artery divided into two or three branches which has either suprapancreatic or anteropancreatic course. Such an aberrant course makes the artery vulnerable to iatrogenic injury during intervention of pancreas.

- We found that the superior polar branch was slender and thin could be easily damaged. To avoid these surgeries on the spleen should be done from the inferior pole.
- To achieve safe splenic embolisation and avoid the risk of pancreatitis, the embolic material should be delivered through the catheter at a distance of 3.1 cm from the hilum.
- It is found that primary branches and polar branches of splenic artery divide the spleen into segments. These segments are separated by avascular planes by segmental branches. In our study the segmental branches were 2 in 84% and 3 in 16%. The segmental branches divided in too many generations but did not show any anastomosis, so they were described as end arteries. This enables partial splenectomy.
- Spleen is exclusively supplied by splenic artery.[11] The segmental blood supply makes segmental resection possible thus could be important where preservation of splenic tissue is necessary.[12]
- Knowledge of variations concerning the CT is of extreme clinical importance in the areas of the Appleby procedure, laparoscopic surgery, and radiological procedures in the upper abdomen, and should be kept in mind by clinicians to avoid complications.[13]
- The anatomical variations of the splenic artery make it vulnerable to iatrogenic injury (Waizer *et al*, 1989). Knowledge of the existing aberrations is important in

planning and conducting surgical procedure. (Oran *et al*, 2001).[2]

### Acknowledgement

I am sincerely thankful to Dr. Aruna Mukherjee for guidance in writing this article. I also thankful to my HOD Dr. Pradeep Pawar for his support and encouragement.

### References

1. Ambica Wadhawa, Sandeep Soni. Composite study of celiac trunk in 30 adult human cadavers-its clinical implications. *Global Journal of Medical Research*. 2011; 11(1).
2. Pande SK, Bhattacharya S, Mishra RN, Shukla VK. Anatomical variations of splenic artery and its clinical implications. *Clinical Anatomy*. 2004; 17(6): 497-502.
3. Romanes GJ. Cunningham's Manual of practical Anatomy: the abdominal cavity; vol 3, 15<sup>th</sup> ed. Oxford: Oxford University Press; 1986, 122-135.
4. Vandamme JPJ, Bonte J. The branches of celiac trunk. *Acta Anat*. 1985; 122: 110-114.
5. Jauregui E. Anatomy of splenic artery. *Rev Fac Clin Med Univ Nac Cordoba*. 1999; 56: 21-41.
6. Mikhail Y Mikhail, R Kamel, NNY Nawar and MFM Rafla. Observations on mode of termination and parenchymal distribution of splenic artery with evidence of splenic lobulation and segmentation. *J Anat*. 1979; 128(2): 253 - 258.
7. Bloom W, Fawcett DW. A textbook of histology: Blood and lymph vascular systems, 10<sup>th</sup> ed. Philadelphia: WB Saunders Company; 1975, 396-404.
8. Sindel Sindel M, Sarikcioglu L, Ceken K. The importance of anatomy of splenic artery and its branches in splenic artery embolisation. *Folia Morphol*. 2001; 60(4): 333-336.
9. Gupta CD, Gupta SC, Arora AK, Jeyasingh P. Vascular segments in human spleen. *Journal of Anatomy*. 1976; 613-616.

10. Padamalata K, Ramesh BS, Balchandra N, Mamtha Y. Accessary splenic artery from left gastroepiploic artery. *International Journal of Anatomical Variations*. 2010; 3: 106-107.
11. Poulin EC, Mammzza J, Schlachta CM. Splenic artery embolisation before laproscopic splenectomy an update. *Surg Endosc*. 1998; 12: 870-875.
12. Lee McGregor's L. Synopsis of surgical anatomy: the spleen, 12<sup>th</sup> ed. KM Varghese Company; 1995: 106-113.
13. Padmi N, Verma S, Vollara VR. Anamolous branching pattern of celiac trunk. *International Journal of Anatomical Variations*. 2008; 1: 8-9.

## Indian Journal of Trauma and Emergency Pediatrics

Handsome offer for subscribers!!

Subscribe **Indian Journal of Trauma and Emergency Pediatrics** and get any one book or both books absolutely free worth Rs.400/-.

### Offer and Subscription detail

*Individual Subscriber*

One year: Rs.1000/- (select any one book to receive absolutely free)

Life membership (valid for 10 years): Rs.5000/- (get both books absolutely free)

Books free for Subscribers of **Indian Journal of Trauma and Emergency Pediatrics**. Please select as per your interest. So, dont' wait and order it now.

*Please note the offer is valid till stock last.*

### CHILD INTELLIGENCE

**By Dr. Rajesh Shukla**

ISBN: 81-901846-1-X, Pb, vi+141 Pages

Rs.150/-, US\$50/-

Published by **World Information Syndicate**

### PEDIATRICS COMPANION

**By Dr. Rajesh Shukla**

ISBN: 81-901846-0-1, Hb, VIII+392 Pages

Rs.250/-, US\$50

Published by **World Information Syndicate**

Order from

**Red Flower Publication Pvt. Ltd.**

48/41-42, DSIDC, Pocket-II, Mayur Vihar, Phase-I

Delhi - 110 091 (India)

Tel: 91-11-22754205, 45796900, Fax: 91-11-22754205

E-mail: redflowerpppl@gmail.com, redflowerpppl@vsnl.net

Website: www.rfpppl.co.in